



The Rare Isolated Solitary Muscle Metastasis of Breast Carcinoma Confirmed by 18F-FDG PET/CT

18F-FDG PET/BT ile Konfirme Edilen Meme Karsinomunun Nadir Görülen İzole Soliter Kas Metastaz Olgusu

Solitary Muscle Metastasis of Breast Cancer

Aynur Özen¹, Eylem Baştuğ¹, Bülent Aşkaroğlu², Özgül Ekmekçioğlu¹, Tülay Kaçar Güveli¹

¹Departments of Nuclear Medicine, ²Radiation Oncology, Bağcılar Training and Research Hospital, İstanbul, Turkey

This case was presented at the 27th Annual Congress of Nuclear Medicine, April 1-5, 2015, Adana-Turkey.

Özet

Meme kanserinin kas dokusuna metastaz yapması oldukça nadirdir. Kas metastazları ise sıklıkla diğer organ metastazları ile birliktedir. İnvaziv duktal karsinoma sahip, uzak metastazı olmayan lokal ileri meme karsinomlu 51 yaşındaki hasta da tanidan 1 yıl sonra solda sternokleidomastoid kasında 5 cm çapında kitle tespit edildi. Bu lezyondan 2 kez biyopsi yapılmasına rağmen malignite lehine bulgu tespit edilmedi. Ancak klinik olarak metastaz düşünülen hastaya yeniden evreleme amacıyla 18F-FDG PET/BT yapıldı. Sol sternokleidomastoid kasındaki hipermetabolik alandan yapılan tru-cut biyopside osteoklast içeren dev hücreli meme karsinomu tespit edildi. Bizim olgumuz ilk metastazını soliter olarak sternokleidomastoid kasına yapan literatürdeki ilk meme karsinomu olgusudur.

Anahtar Kelimeler

Meme Kanseri; Fluorodeoksiglukoz F18; Metastaz; Kas-İskelet Sistemi

Abstract

Muscle metastasis of breast carcinoma is a rare condition. It often coexists with other organ metastases. A mass in the left sternocleidomastoid muscle was detected 1 year after diagnosis in a 51-year-old patient with locally advanced invasive ductal breast carcinoma. Although biopsy from this lesion was applied two times, the malignancy was not found. However, the patient had clinically-suspected metastasis. The 18F-FDG PET/CT was performed for restaging. The tru-cut biopsy from the hypermetabolic area in muscle mass proved the metastasis contained osteoclast giant cell carcinoma of the breast. Our patient is the first case in the literature of the diagnosis of breast cancer with initial solitary metastasis to the sternocleidomastoid muscle.

Keywords

Breast Cancer; Fluorodeoxyglucose F18; Metastasis; Musculoskeletal System

DOI: 10.4328/JCAM.4023

Received: 06.01.2016

Accepted: 09.03.2016

Printed: 01.07.2016

J Clin Anal Med 2016;7(4): 557-9

Corresponding Author: Aynur Özen, İnönü Mah. Üftade Sok. No:37/6 Şişli, İstanbul, Turkey.

T.: +90 2124404000/3266, F.: +90 2124404013 E-Mail: ozenaynur@gmail.com

Introduction

Breast carcinoma is the most common cancer in women. Positron emission tomography/computed tomography (PET/CT) hybrid scanner using 18flour-fluorodeoxyglucose (18F-FDG) allows for molecular imaging as well as the possibility of learning about both tumor metabolism and the anatomical structure. In breast carcinoma, 18F-FDG PET/CT is applied for evaluation with advanced stage and metastatic breast cancer staging, restaging, to predict response to therapy, and for radiation therapy planning [1]. Also, 18F-FDG PET/CT is useful to determine the location for biopsy in patients with the suspicion of malignancy but in whom previous biopsy was negative. Although breast cancer metastasizes to any organ and frequently recurs, muscle tissue metastasis is very rare. Muscle metastasis in this group of patients is often associated with multiple organ metastasis. Metastases to the muscles of different types of tumors have been reported in a few cases in the literature [2-4].

Case Report

A 51-year-old female patient had a palpable mass in the left breast; biopsy detected invasive ductal carcinoma. Left mastectomy and axillary dissection was performed on the patient. In pathological examination, tumor size was 4 cm, 12 of 29 lymph nodes had metastases, and lymphovascular and perineural invasion were detected. In immunohistochemical evaluation, oestrogen and progesterone receptor was negative, while c-erb2 receptor was 3+. Radiotherapy and chemotherapy including adriamycin, cyclophosphamide, taxane, and trastuzumab was undergone by the patient. After 1 year of follow-up, a palpable mass of about 5 cm in diameter was detected in the left sternocleidomastoid (SCM) muscle. Magnetic resonance imaging showed an encapsulated mass lesion with contrast enhanced cystic and solid components at inferior site of SCM muscle. The tru-cut biopsy was performed for pathologic diagnosis. Connective tissue fragment containing atypical cells was found. Then, biopsy was repeated with fine-needle, but there was blood fragment and the biopsy failed to obtain adequate tissue. However, the suspicion of malignancy was strong clinically and in magnetic resonance imaging. Therefore, 18F-FDG PET/CT scan was performed to determine the location of the biopsy area and for restaging. The mass lesion muscle in the left supraclavicular region of the inferior segment of left SCM muscle with increased heterogeneous FDG uptake (SUVmax: 5.6) and approximately 42x48 mm in size was observed (Figure 1). In other areas, it did not reveal any findings of metastasis. The tru-cut biopsy from the hypermetabolical region of mass showed metastasis of breast carcinoma with giant cell lesions containing osteoclasts.

Discussion

Muscle metastases are often asymptomatic and are found incidentally on imaging. In CT imaging, clear distinction cannot always be made between muscle and an intramuscular metastatic lesion because their density is so similar. Magnetic resonance imaging is also more expensive than CT and it takes a long time to display for large areas. Therefore, 18F-FDG PET/CT has some advantages over CT such as better detection of muscle lesion, to exclude other distant metastases, and to guide to the

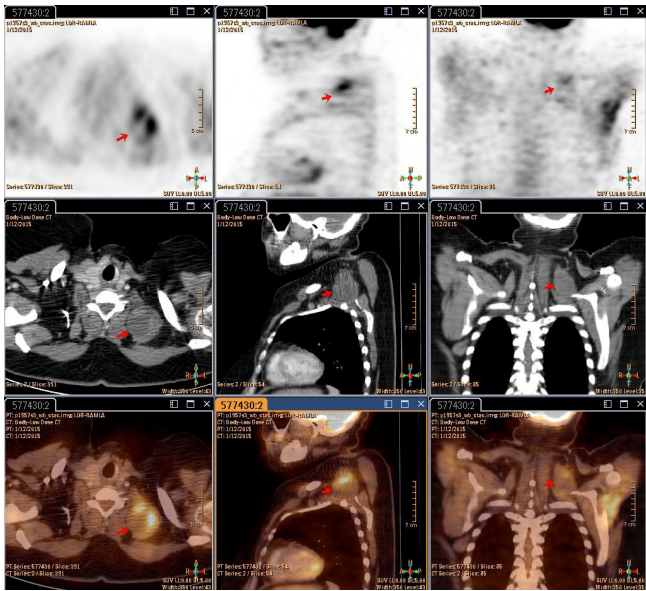


Figure 1. The heterogeneous 18F-FDG uptake at palpable mass in left SCM muscle.

biopsy area. In a retrospective study, records of 8492 patients were examined and muscle metastases in PET/CT were determined in 73 (0.86%) patients. Sources of metastasis were: lung 34%, gastrointestinal tract 18%, breast 14%, genitourinary malignancy and lymphoma 8%, melanoma 7%, and other malignancies 4%. In this study, most patients had visceral metastases with stage IV disease, while PET/CT showed unexpectedly widespread muscle involvement. Thus, muscle involvement did not lead to an increase in staging [5].

The muscular system is relatively resistant to metastatic disease. The factors for resistance are muscle movement causing mechanical tumor destruction, muscle pH, tumor removal ability of lactic acid production associated with muscle angiogenesis, the activation of lymphocytes, and natural killer cells in the muscular system [6-7]. However, in large autopsy series it is more evident than in the subclinical muscle metastases; incidence varies between 0.2% and 17.5% [7-8].

The sites of intramuscular metastasis of breast carcinoma in the literature are the muscles of gluteus medius, rectus abdominus, and extraocular. Although these have been stated that this solitary three of the cases, it is doubtful in the light of current knowledge that published prior to the entry into clinical use of 18F-FDG PET/CT. Our case is the first breast carcinoma with solitary SCM muscle metastasis reported in the literature. The metastasis in this case was not proven by repeated biopsy, and PET/CT performed for restaging has been useful for guiding to the biopsy area and for identifying distant metastases.

Competing interests

The authors declare that they have no competing interests.

References

1. Ozen A. The Evaluation of Primary Lesion and Axillary Metastasis in Breast Carcinoma By 18F-FDG PET/CT. J Clin Anal Med 2015; DOI: 10.4328/JCAM.3272
2. Acinas García O, Fernández FA, Satué EG, Buelta L, Val-Bernal JF. Metastasis of malignant neoplasms to skeletal muscle. Rev Esp Oncol 1984;31(1):57-67.
3. Camnasio F, Scotti C, Borri A, Fontana F, Fraschini G. Solitary psoas muscle metastasis from renal cell carcinoma. ANZ J Surg 2010;80(6):466-7.
4. Girard M, Kelkel E, Peoch M, Grand S, Massot C. Metastasis in the psoas muscle disclosing breast carcinoma. Ann Med Interne (Paris) 1992;143(7):492-44.
5. Doo SW, Kim WB, Kim BK, Yang WJ, Yoon JH, Song YS, et al. Skeletal muscle metastases from urothelial cell carcinoma. Korean J Urol 2012;53(1):63-6.

6. Khandelwal AR, Takalkar AM, Lilien DL, Ravi A. Skeletal muscle metastases on FDG PET/CT imaging. Clin Nucl Med. 2012 Jun;37(6):575-9.
7. Molina-Garrido MJ, Guillén-Ponce C. Muscle metastasis of carcinoma. Clin Transl Oncol 2011;13(2):98-101.
8. Emmering J, Vogel WV, Stokkel MP. Intramuscular metastases on FDG PET-CT: a review of the literature. Nucl Med Commun 2012;33(2):117-20.

How to cite this article:

Özen A, Baştuğ E, Aşkaroğlu B, Ekmekçioğlu Ö, Güveli TK. The Rare Isolated Solitary Muscle Metastasis of Breast Carcinoma Confirmed by 18F-FDG PET/CT. J Clin Anal Med 2016;7(4): 557-9.